

## Management of Canine perianal fistula with fluorescence light energy: preliminary findings

Andrea Marchegiani\* , Adolfo M. Tambella\* , Alessandro Fruganti\*, Andrea Spaterna\*, Matteo Cerquetella\* and Susan Paterson† 

\*School of Biosciences and Veterinary Medicine, University of Camerino, via Circonvallazione 93/95, Matelica, Marche, I-62024, Italy

†Virtual Vet Derms Ltd., Lakeview, 3 High Birkrigg Park, Stainton, Kendal, LA8 0DY, UK

Correspondence: Andrea Marchegiani, School of Biosciences and Veterinary Medicine, University of Camerino, Via Circonvallazione 93/95, I-62024 Matelica, Marche, Italy. E-mail: andrea.marchegiani@unicam.it

**Background** – Canine perianal fistula (CPF) is a severe, painful, debilitating skin condition affecting the perianal skin. It often interferes with the quality of life of both dog and owner. Conventional medical treatment involves the use of immunosuppressive therapy; however, the successful resolution of lesions can be limited by poor owner compliance, adverse drug effects and dependence on costly therapies.

**Hypothesis/Objectives** – The present study aimed to assess the potential benefits of fluorescent light energy (FLE) on cases of CPF.

**Animals** – Four dogs with active perianal fistulas

**Methods and materials** – FLE was applied as sole management therapy once a week with two consecutive applications in the same session for each dog until clinical signs had significantly improved, with weekly assessments for a six week period. Dogs were assessed by measuring the size of lesions at the start of the study and then weekly for six weeks, using planimetry software. Owners recorded vocalization and straining frequency scores during their pet's defaecation, and perianal licking frequency on a 0–5 point scale to assess the response to therapy.

**Results** – All dogs improved with FLE, achieving a significant reduction in vocalization, straining and licking after two weeks ( $P = 0.002$ ). After five weeks of FLE therapy, lesional areas had significantly decreased ( $P = 0.04$ ). Only one dog required more than seven applications. No adverse events were reported.

**Conclusion and clinical importance** – FLE may be a promising alternative therapy for CPF.

### Introduction

Canine perianal fistulas (CPF) are painful, chronic inflammatory sinus tracts and ulcers that develop spontaneously in the perianal skin, most commonly in German shepherd dogs (GSD).<sup>1</sup> More than 80% of all reported cases have been recognised in the GSD, suggesting there may be a genetic component to disease susceptibility in this breed. An immune-mediated aetiopathogenesis has been postulated as a cause of CPF. This is due to the presence of T-cell infiltrates in lesional skin with upregulated cytokine production and the response to medical therapy with immunosuppressive drugs.<sup>2,3</sup> CPF is a debilitating condition and is known to have a negative impact on the quality-of-life (QoL) of affected dogs and can result

in euthanasia if not managed effectively.<sup>1</sup> It is therefore imperative that the disease is diagnosed early in its course and aggressive medical therapy is instituted at the earliest opportunity. Although not licensed for use in CPF, systemic ciclosporin and topical tacrolimus are recognised by many authors as the treatments of choice for this disease.<sup>4–6</sup> However, despite their high level of efficacy and the low incidence of reported adverse effects as treatment modalities, they are not tolerated by all patients and can be prohibitively expensive for some owners. Other immunomodulatory agents that have been used to treat CPF include oral prednisolone<sup>7</sup> (at initial immunosuppressive doses), azathioprine<sup>8</sup> and mycophenolate mofetil.<sup>9</sup> Whilst prednisolone has been shown to be effective when used with a commercially available novel protein diet, the risk of adverse effects with chronic glucocorticoids administration makes this an unsuitable drug for long-term control.<sup>7</sup> Azathioprine has been shown to be successful in 57% of dogs when used to treat CPF, yet this relatively low rate of resolution together with the need for long-term laboratory monitoring does not make this a better choice than calcineurin inhibitors.<sup>8</sup> Mycophenolate mofetil failed to show efficacy, albeit in a small number of CPF cases.<sup>9</sup>

Fluorescence light energy (FLE) has recently been shown to produce benefits as an adjunctive therapy in the

Accepted 27 June 2020

**Sources of Funding:** This study was self-funded.

**Conflicts of Interest:** Klox Technologies Limited currently funds a full-time research position at the University of Camerino. Susan Paterson is a consultant for Klox and ICF. Over the last two years, she has received honoraria or hospitality from Elanco, Dechra and Royal Canin. All remaining authors are not consultants nor have received any honorarium from Klox Technologies Limited or other pharmaceutical companies in the veterinary dermatology field

management of cases of canine pyoderma.<sup>10–12</sup> In addition to its ability to improve the speed of resolution of infection it also has been shown to promote all three phases of wound healing.<sup>13</sup> A recent study showed FLE resulted in improved re-epithelialization, decreased dermal inflammation and improved matrix formation in canine cutaneous incisional wounds, by regulating the expression of key biological mediators such as Factor VIII, Epidural Growth Factor and Tumour Necrosis Factor (TNF) alpha.<sup>14</sup> In addition, FLE decreases the inflammation of treated tissues through the downregulation of TNF $\alpha$  and interleukin (IL)-6,<sup>14,15</sup> having a beneficial role in both immune-mediated and inflammatory diseases.<sup>16</sup> The Klox FLE System (Phovia, Klox Technologies Limited, Dublin, Ireland) consists of a blue light-emitting diode (LED) device and topical photoconverter gel, which when illuminated by the LED device emits low energy light in the form of fluorescence. The aim of this small open label study was to evaluate the effect of FLE on confirmed cases of CPF. The present study was designed to assess (i) improvement in the extent of perianal lesions and (ii) reduction in clinical signs of vocalisation and discomfort on defaecation.

## Methods and materials

Four dogs referred to the veterinary hospital at the onset of a CPF episode were included in this prospective, interventional study. All owners were offered biopsy of the lesions in the perianal area and investigation of large bowel disease including colonic biopsies, to confirm the diagnosis histopathologically and to determine whether colitis was present. Both options were declined in all cases.

A diagnosis of CPF was therefore made on the basis of the characteristic gross presentation of the lesions in GSD as described previously.<sup>1</sup>

At the time of presentation, none of the dogs were being treated with any antimicrobial drug or antiseptic product, nor had they been in the previous 14 days. Likewise, none of the dogs had been treated with immunomodulatory therapies (ciclosporin or prednisolone) in the previous 30 days. The study protocol was approved by the institutional animal care and use committee of University of Camerino, and written informed consent was obtained from all dog owners before enrolment in the study. Owners were adequately informed that the intervention was experimental in nature and that animal use was in compliance with local national guidelines for ethical use of animals in research; informed owner consent included the ability to withdraw

their dog from the trial and restart ciclosporin therapy if they felt their dog was unacceptably uncomfortable. An increase in vocalization, straining or licking frequency, as well as any owners' perception of discomfort in the dog, represented criteria for early study withdrawal after FLE therapy was started.

A complete history was obtained and a general clinical examination, routine blood tests (complete blood count, serum biochemical evaluation and electrophoresis) and urinalysis were performed. Only dogs with parameters within the normal range and without the presence of other conditions/diseases as assessed by a thorough clinical history and physical examination that mandated immediate treatment were enrolled. None of the dogs at the commencement of the study showed any signs of gastrointestinal disease in the form of vomiting or diarrhoea and although owners consistently reported signs of faecal tenesmus and haematochezia, changes in stool consistency or the presence of diarrhoea were not reported and therefore not used as ongoing assessment criteria.

## Scoring system

Anal sacs were examined and were found not to be involved in any dog. Cases with suspected or confirmed neoplasia were excluded from this study. The presence of any communication between cutaneous sinus tracts and the rectal lumen also was considered to be an exclusion criterion. Before every FLE application, the perianal area was visually inspected and palpated to highlight any modification of CPF in appearance and consistency. All of the dogs were on a commercial hypoallergenic diet (Table 1) when referred and no changes were made to their diets over the complete duration of the study.

Any changes in CPF were evaluated using the following criteria. The size of lesions was measured at baseline (T0) and then weekly until complete healing using planimetry software (PHOTOSHOP CS5 extended version, Adobe Systems Inc.; Mountain View, CA, USA). Although this method of lesion assessment only considers the size and not the depth of the lesions, it was chosen as being the most noninvasive method of ongoing measurement. As weekly sedation to measure lesion depth was not considered to be ethically acceptable, it was not performed.

All lesions were assessed during the weekly clinical examination by the same author to avoid missing small lesions. Dyschezia was evaluated by vocalization and straining frequency scores, recorded by pet owners when their dogs defaecated, and discomfort was evaluated by licking frequency scores, also recorded by pet owners. Table 2 shows the 0–5 point scales that were designed for the study, allowing a maximum combined score of 15.

Once clinical improvement and a decrease in lesional areas were achieved, patients were enrolled for a six month follow-up period to assess any recurrence of CPF. During the follow-up period, owners were asked to contact the hospital if they observed any signs of recurrence of the lesions or clinical signs associated with CPF. In

**Table 1.** Description of signalment data for four enrolled German shepherd dogs (all long haired): recurrence rate, previous medical therapy and outcome, feeding regime and number of fluorescence light energy (FLA) applications to achieve significant improvement

Dog #	Signalment data			Duration of clinical signs (years)	Previous medical therapy		Feeding regimen at referral	Number of FLA applications (weeks) until significant improvement achieved
	Sex	Age (years)	Weight (kg)		Antimicrobial agents	Immunosuppressive agents		
1	Male	6	48	3	Amoxicillin and clavulanic acid, metronidazole and spyramicin, enrofloxacin replaced after a week by pradofloxacin	Ciclosporin and prednisolone	Royal Canin hypoallergenic	6
2	Male	3	36	2	Amoxicillin and clavulanic acid	None	Royal Canin hypoallergenic	5
3	female	12	34	4	Cephalexin and enrofloxacin	None	Hill's d/d	4
4	female	9	35	1	Amoxicillin and clavulanic acid, metronidazole and spyramicin, enrofloxacin, cephalexin	Ciclosporin and prednisolone	Hill's z/d	13

**Table 2.** The 0–5 point scoring scale for dyschezia and discomfort in dogs

Score	Vocalization	Straining	Licking
0	No vocalization	No straining	No licking
1	Weekly, not daily	Weekly, not daily	1–2 times a day
2	Daily, not every defaecation	Daily, not every defaecation	3–6 times a day
3	1–2 vocalizations every defaecation	1–2 straining occurrences every defaecation	7 times a day to hourly
4	2–4 vocalizations every defaecation	2–4 straining occurrences every defaecation	Hourly to every 15 min
5	≥5 vocalizations every defaecation	≥5 straining occurrences every defaecation	More than once every 15 min

addition, all owners were contacted by phone weekly for two months and then monthly for four months after clinical resolution to check if any signs of relapse were noticed or whether the dog had required any antimicrobial or anti-inflammatory therapy for CPF or any other condition. All owners were required to attend a final clinical examination, six months after the start of the follow-up period.

### FLE protocol

The FLE therapy was administered only to the affected perianal skin. It was applied to conscious dogs without the need for sedation or analgesia. The FLE procedure consisted of applying an approximately 2 mm layer of the gel to the lesions and illuminating them with the blue LED device. This delivers noncoherent blue light with peak wavelength between 440 and 460 nm and power density between 55 and 129 mW/cm<sup>2</sup>, for 2 min, at approximately 5 cm distance. This protocol was applied once a week with two consecutive applications in the same session for each dog and no concomitant medications (antimicrobials nor immunosuppressants) were allowed. After each illumination, the gel was gently removed using sterile gauze immersed in sterile saline solution. Owners were encouraged to maintain high levels of hygiene of the perianal region using the same cleansing procedure recommended before, consisting of multiple rinses of the affected areas with sterile saline solution. If needed, clipping of the hair was repeated by investigators at therapy visits.

### Statistical analysis

Data were reported using mean and standard deviation (SD), or median and ranges as appropriate. Multiple comparisons by study time were performed with data collected during the study. Vocalization, straining and licking scores were analysed using the Friedman test, while lesion areas were analysed with ANOVA for repeated measures. A *P*-value <0.05 was considered statistically significant. All data were analysed statistically with SAS v9.4 (SAS Institute, Cary, NC, USA).

### Results

Table 1 shows the signalment details for each dog, the CPF history and treatment protocols received by each dog before referral, as well as the number of FLE applications received. All dogs were GSD and the average age and weight ( $\pm$ SD) were  $7.5 \pm 3.9$  years and  $38.25 \pm 6.55$  kg, respectively. At enrolment, all dogs presented with clinical signs consistent with CPF and with different severity levels. Clinical signs included tenesmus, haematochezia, and an ulcerated malodorous perianal region with draining fistulous tract, resulting in pain, discomfort, licking and inability to sit. Two of the four dogs (cases 1 and 4) also presented with anorexia, weight loss and increased aggressive behaviour.

All dogs showed reduction of CPF areas related to the FLE application (Figure 1); however, an increase in lesional areas was observed after the initial FLE applications in Week 2 for cases 1, 3 and 4, and in Week 3 for cases 1 and 4 (Fig. 4 and Table S1). After four weeks of

treatments, all dogs showed a decrease in lesional areas of 74.29% on average, when compared with T0. By Week 6, three of four dogs were considered well enough clinically to stop the FLE sessions. Only one dog required more than seven applications (Figure 2); no adverse events were reported by owners or noted by investigators. No recurrence was observed by owners within the first six months after cessation of the therapy, and visual inspection of the treated areas by the investigators after a period of six months showed no evidence of lesion recurrence.

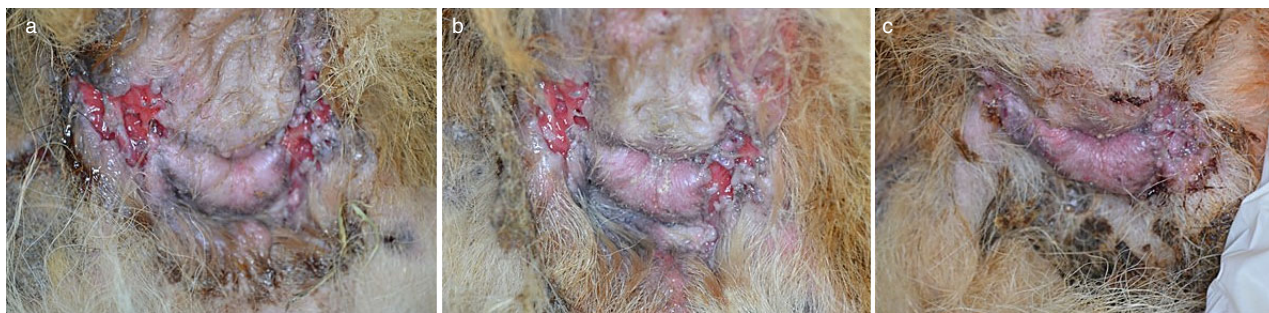Figure 3 shows the weekly median scores for lesional areas up to Week 6. Figure 4 shows the weekly scores for lesional areas for each individual dog. Figure 5 shows the pet owner weekly scores for dyschezia (vocalization and straining) and discomfort (perianal licking).

Improvements in the median dyschezia and discomfort scores were statistically significant from Week 2 (*P* = 0.002). At this time point (after two FLE sessions) the total median scores had dropped to less than half the initial score; investigators noted that swelling and pain at palpation were by that time not noticeable in any of the four cases and that all dogs had regained the ability to sit without pain, as corroborated by the pet owners.

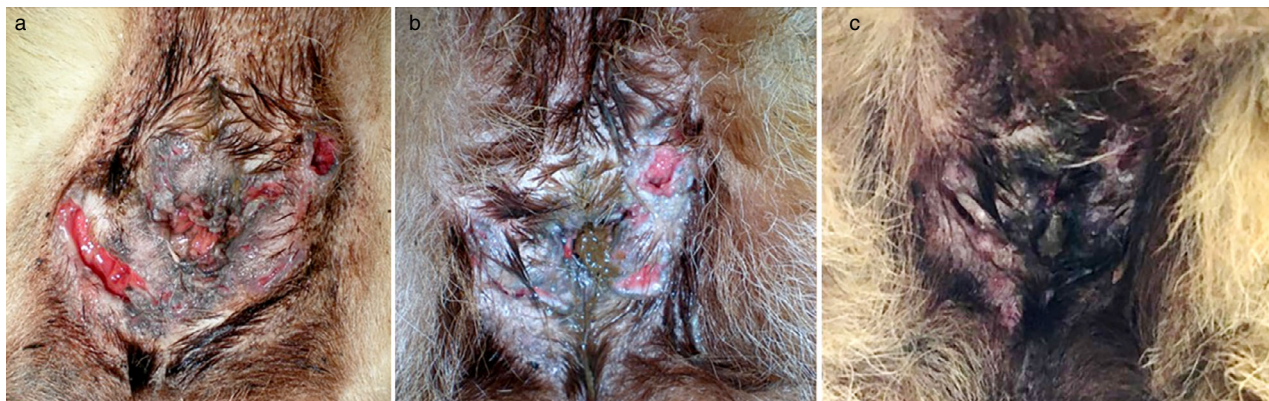### Discussion

The use of FLE in this study to manage four dogs with CPF produced significant and long-term improvement in all aspects of their disease. All dogs demonstrated a >90% improvement in the extent of their perianal lesions together with a resolution of all signs of tenesmus, dyschezia and vocalisation on defaecation. The therapy was well-tolerated by all dogs, including the product application to the affected perianal skin without the need for excessive restraint, sedation or analgesia. No adverse effects were recorded in response to therapy in any dog.

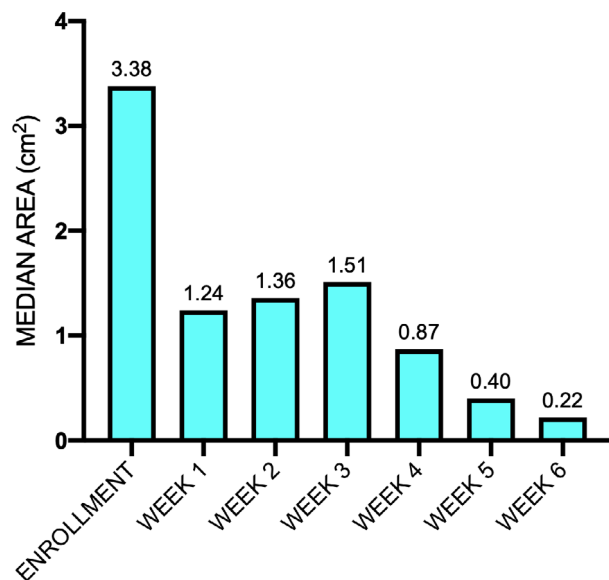
The pathogenesis of CPF is poorly defined. Initial hypotheses that it is a consequence of the anatomical conformation of the GSD have mostly been superseded by those proposing an immune-mediated pathogenesis.<sup>3</sup> Histopathological examination of resected tissue from CPF cases have revealed the presence of a mononuclear cell infiltration, including large numbers of CD3+ T lymphocytes.<sup>2</sup> The cytokine mRNA profile in CPF lesions also is consistent with T-cell mediated inflammation increasing expression of IL-2 and interferon gamma (IFN  $\gamma$ ) in the tissue of affected dogs compared to controls.<sup>17</sup> This evidence, together with the response of the disease to ciclosporin, which is known to suppress T-cell activation by blocking IL-2 expression, suggests an immune-



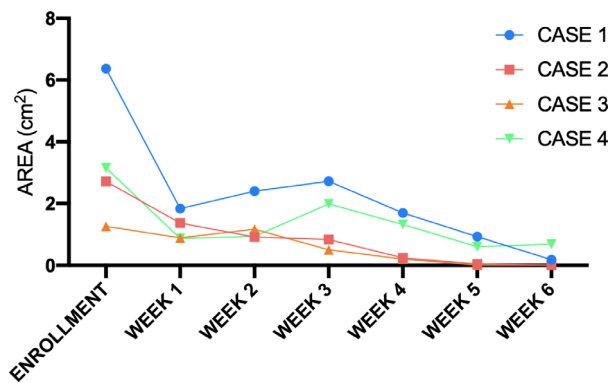
**Figure 1.** Case 2: German shepherd dog with perianal fistula treated with fluorescence light energy, clinical evaluation. (a) Enrolment visit, (b) Week 2 visit and (c) Week 4 visit, showing significant clinical improvement.



**Figure 2.** Case 4: German shepherd dog with perianal fistula treated with fluorescence light energy, clinical evaluation. (a) Enrolment visit, (b) Week 6 visit and (c) Week 13 visit. Although small residual fistulas were still present at the final visit, significant clinical improvement was seen.



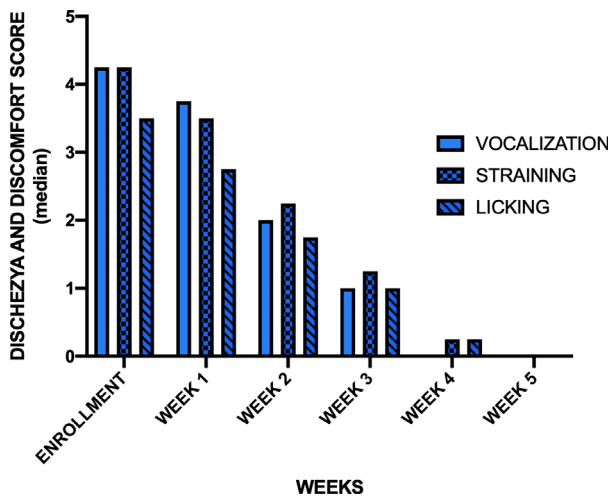
**Figure 3.** Median weekly lesional areas in German shepherd dogs with perianal fistulae treated with fluorescence light energy.



**Figure 4.** Weekly lesional areas by case in German shepherd dogs with perianal fistulae treated with fluorescence light energy.

mediated pathogenesis for CPF. Abnormal macrophage activation by Type 1 helper T cells also has been suggested to play a role in the evolution of lesions. One study found increased expression of matrix metalloproteinase

(MMP)-9 and MMP-13 mRNA in lesional skin from cases of CPF compared to controls, suggesting that dogs with disease may have an impaired ability to initiate wound repair, leading to the persistence of clinical lesions.<sup>18</sup> Recent studies investigating the skin microbiota in hidradenitis suppurativa (HS), a similar chronic auto-inflammatory skin disease in man, have shown significant differences in the cutaneous microbiota between non-lesional skin in affected individuals and healthy controls.<sup>19</sup> Whilst HS has an immune-mediated pathogenesis, the improvement that is seen with antimicrobial therapy in



**Figure 5.** Median weekly scores for dyschezia (vocalization, straining) and discomfort (licking) in German shepherd dogs with perianal fistulae treated with fluorescence light energy.

A statistically significant improvement was seen starting from Week 2.

this disease may be due to the benefits such treatment have on the skin dysbiosis.

It is unclear why therapy with FLE led to improvement in clinical lesions in these four cases of CPF. It may be that the ability of FLE to enhance collagen production, modulate cutaneous inflammation and encourage angiogenesis in inflammatory skin conditions enhanced and accelerated the healing process.<sup>15</sup> In human dermal fibroblast and epidermal keratinocytes, FLE has been shown to reduce output of TNF- $\alpha$  and IL-6 which are often implicated in triggering and maintaining chronic skin inflammation.<sup>15</sup> Improvements in comfort levels following FLE therapy previously were reported in human venous leg ulcers, where pain scores showed a rapid decrease after treatment initiation.<sup>20</sup> Furthermore, studies in dogs and humans have suggested that the positive effects of FLE may persist after the therapy has been stopped, which may help keep animals in remission. An extension study on human acne demonstrated a persistence of efficacy duration of six months on the hemiface treated during the main trial.<sup>21</sup> In a canine interdigital pyoderma study, dogs in the FLE group showed a lower disease recurrence level.<sup>9</sup> Likewise, in human chronic wounds, patients treated with FLE showed an extremely low rate of wound breakdown.<sup>19</sup> If skin dysbiosis does occur in CPF, as it does in other inflammatory canine skin problems such as canine atopic dermatitis (cAD),<sup>22</sup> it is possible that FLE helps control bacterial growth by mimicking the effect of antimicrobial administration, which has been shown to improve skin dysbiosis in cAD.<sup>23</sup> Future work might include evaluation of the cutaneous microbial populations of the perianal skin in dogs before and after therapy with FLE.

Pain relief produced by FLE application, in patients suffering with pressure sores and ulcers has been shown to improve their QoL. The present study omitted to undertake a QoL assessment for dogs and owners. This is something that should be included in any subsequent work, particularly to compare the QoL of the standard-of-

care medical therapy for this condition (immunosuppressive drugs) with the QoL of FLE.

The results from this small exploratory study suggest that FLE may be a useful therapy for cases of CPF. It represents a convenient, effective and safe form of therapy, with the potential for long periods of remission post-therapy. There is now a need for larger controlled trials to confirm these preliminary findings. These should be designed to compare the response of clinical cases of CPF to FLE and an appropriate standard-of-care protocol using immunomodulatory therapy with ciclosporin.

## Acknowledgement

The authors gratefully acknowledge Ricardo Garvao for his contributions in providing insight and expertise that greatly assisted the writing of this paper.

## References

- Cain CL. Canine perianal fistulas: clinical presentation, pathogenesis, and management. *Vet Clin North Am Small Anim Pract* 2019; 49: 53–65.
- Day MJ, Weaver BMQ. Pathology of surgically resected tissue from 305 cases of anal furunculosis in the dog. *J Small Anim Pract* 1992; 33: 583–589.
- Day MJ. Immunopathology of anal furunculosis in the dog. *J Small Anim Pract* 1993; 34: 381–389.
- Doust R, Griffiths LG, Sullivan M. Evaluation of once daily treatment with cyclosporine for anal furunculosis in dogs. *Vet Rec* 2003; 152: 225–229.
- Hardie RJ, Gregory SP, Tomlin J, et al. Cyclosporine treatment of anal furunculosis in 26 dogs. *J Small Anim Pract* 2005; 46: 3–9.
- Stanley BJ, Hauptman JG. Long-term prospective evaluation of topically applied 0.1% tacrolimus ointment for treatment of perianal sinuses in dogs. *J Am Vet Med Assoc* 2009; 235: 397–404.
- Harkin KR, Walshaw R, Mullaney TP. Association of perianal fistula and colitis in the German shepherd dog: response to high-dose prednisone and dietary therapy. *J Am Anim Hosp Assoc* 1996; 32: 515–520.
- Tisdall PL, Hunt GB, Beck JA, et al. Management of perianal fistulae in five dogs using azathioprine and metronidazole prior to surgery. *Aust Vet J* 1999; 77: 374–378.
- Ackermann AL, May ER, Frank LA. Use of mycophenolate mofetil to treat immune-mediated skin disease in 14 dogs – a retrospective evaluation. *Vet Dermatol* 2017; 28: 195–e44.
- Marchegiani A, Cerquetella M, Tambella AM, et al. The Klox Biophotonic System, an innovative and integrated approach for the treatment of deep pyoderma in dogs: a preliminary report. *Vet Dermatol* 2017; 28: 545 (abstract).
- Marchegiani A. Klox Fluorescence Biomodulation System (KFBS), an alternative approach for the treatment of superficial pyoderma in dogs: preliminary results. In: Proceedings of 61st British Small Animal Veterinary Association (BSAVA) Congress; Birmingham, UK. British Small Animal Veterinary Association, Birmingham, UK: 2018; 442.
- Marchegiani A, Spaterna A, Cerquetella M, et al. Fluorescence biomodulation in the management of canine interdigital pyoderma cases: a prospective, single-blinded, randomized and controlled clinical study. *Vet Dermatol* 2019; 30: 371–e109.
- Salvaggio A, Magi GE, Rossi G, et al. Effect of the topical Klox fluorescence biomodulation system on the healing of canine surgical wounds. *Vet Surg* 2020; 49: 719–727.
- Scapagnini G, Marchegiani A, Rossi G. Management of all three phases of wound healing through the induction of fluorescence biomodulation using fluorescence light energy. In: Proceedings Volume 10863, Photonic Diagnosis and Treatment

- of Infections and Inflammatory Diseases II; SPIE BIOS 2019; San Francisco, CA, USA (<https://doi.org/10.1117/12.2508066>).
15. Edge D, Møllergaard M, Dam-Hansen C. Fluorescent Light Energy: the future for treating inflammatory skin conditions? *J Clin Aesthet Dermatol* 2019; 12: E61–E68.
  16. Hamblin MR. Mechanisms and applications of the anti-inflammatory effects of photobiomodulation. *AIMS Biophys* 2017; 4: 337–361.
  17. House A, Gregory SP, Catchpole B. Expression of cytokine mRNA in canine anal furunculosis lesions. *Vet Rec* 2003; 153: 354–358.
  18. House AK, Catchpole B, Gregory SP. Matrix metalloproteinase mRNA expression in canine anal furunculosis lesions. *Vet Immunol Immunopathol* 2007; 115: 68–75.
  19. Langan EA, Recke A, Bokor-Billmann T, et al. The role of the cutaneous microbiome in hidradenitis suppurativa—light at the end of the microbiological tunnel. *Int J Mol Sci* 2020; 11: 1,205.
  20. Romanelli M, Piaggese A, Scapagnini G, et al. EUREKA study - The evaluation of real-life use of a biophotonic system in chronic wound management: an interim analysis. *Drug Res Devel Ther* 2017; 11: 3,551–3,558.
  21. Nikolis A, Fauverge S, Scapagnini G, et al. An extension of a multicenter, randomized, split-face clinical trial evaluating the efficacy and safety of chromophore gel-assisted blue light phototherapy for the treatment of acne. *Int J Dermatol* 2018; 57: 94–103.
  22. Rodrigues Hoffmann A. The cutaneous ecosystem: the roles of the skin microbiome in health and its association with inflammatory skin conditions in humans and animals. *Vet Dermatol* 2017; 28: 60–e15.
  23. Bradley CW, Morris DO, Rankin SC, et al. Longitudinal evaluation of the skin microbiome and association with microenvironment and treatment in canine atopic dermatitis. *J Invest Dermatol* 2016; 136: 1,182–1,190.

## Supporting Information

Additional Supporting Information may be found in the online version of this article.

**Table S1.** Summary of weekly median fistula area, dyschezia and discomfort scores for each patient

### Résumé

**Contexte** – Les fistules anales canines (CPF) sont une dermatose sévère, douloureuse et invalidante de la peau périanale. Elle interfère souvent avec la qualité de vie du chien comme de son propriétaire. Les traitements médicaux conventionnels impliquent les immunosuppresseurs ; cependant, la résolution des lésions peut être limitée par la faible compliance du propriétaire, les effets indésirables des traitements et leur coût.

**Hypothèses/Objectifs** – Cette étude a pour objectif de déterminer les effets bénéfiques potentiels de la lumière fluorescente (FLE) sur des cas de CPF.

**Sujets** – Quatre chiens avec fistules périanales actives.

**Matériels et méthodes** – FLE a été appliqué en traitement unique une fois par semaine, deux fois consécutives au cours de la même session pour chaque chien jusqu'à amélioration clinique significative avec évaluation chaque semaine pendant six semaines. Les chiens étaient évalués par la mesure de la taille des lésions au départ et chaque semaine pendant six semaines, à l'aide d'un logiciel de planimétrie. Les propriétaires notaient les vocalises et les efforts de poussée au cours de la défécation de leur animal ainsi que la fréquence de léchage sur une échelle de 0 à 5 pour déterminer la réponse au traitement.

**Résultats** – Tous les chiens se sont améliorés avec FLE, avec une réduction significative des vocalises, poussées et léchage après deux semaines ( $P = 0.002$ ). Après cinq semaines de traitement FLE, les zones lésionnelles avaient significativement diminuées ( $P = 0.04$ ). Seulement un chien a nécessité plus de sept applications. Aucun effet secondaire n'a été décrit.

**Conclusion et importance clinique** – FLE semble être un traitement alternatif prometteur de CPF.

### Resumen

**Introducción** – la fístula perianal canina (CPF) es una afección cutánea grave, dolorosa y debilitante que afecta la piel perianal. A menudo interfiere con la calidad de vida tanto del perro como del dueño. El tratamiento médico convencional implica el uso de terapia inmunosupresora; sin embargo, la resolución exitosa de las lesiones puede verse limitada por el cumplimiento deficiente del propietario, los efectos adversos de los medicamentos y la dependencia de terapias costosas.

**Hipótesis/Objetivos** – El presente estudio tuvo como objetivo evaluar los beneficios potenciales de la energía de la luz fluorescente (FLE) en los casos de CPF.

**Animales** – cuatro perros con fístulas perianales activas.

**Métodos y materiales** – la FLE se aplicó como única terapia de manejo una vez por semana con dos aplicaciones consecutivas en la misma sesión para cada perro hasta que los signos clínicos mejoraron significativamente, con evaluaciones semanales durante un período de seis semanas. Los perros se evaluaron midiendo el tamaño de las lesiones al comienzo del estudio y luego semanalmente durante seis semanas, utilizando un software de planimetría. Los propietarios registraron puntuaciones de frecuencia de vocalización y esfuerzo durante la defecación de su mascota y la frecuencia de lamido perianal en una escala de 0 a 5 puntos para evaluar la respuesta a la terapia.

**Resultados** – todos los perros mejoraron con FLE, logrando una reducción significativa en la vocalización, el esfuerzo y lamidos después de dos semanas ( $P = 0,002$ ). Después de cinco semanas de terapia con FLE, las áreas lesionadas habían disminuido significativamente ( $P = 0,04$ ). Solo un perro requirió más de siete aplicaciones. No se reportó ningún evento adverso.

**Conclusión e importancia clínica** – la FLE puede ser una terapia alternativa prometedora para la CPF.

## Zusammenfassung

**Hintergrund** – Perianale Fisteln des Hundes (CPF) sind schwere, schmerzhafte, schwächende Hauterkrankungen, die die perianale Haut betreffen. Es beeinträchtigt häufig die Lebensqualität von Hunden wie auch ihrer BesitzerInnen. Eine konventionelle medizinische Behandlung besteht aus einer immunsuppressiven Therapie; es kann jedoch eine erfolgreiche Abheilung der Veränderungen durch schlechte BesitzerInnen Compliance, durch Medikamenten Nebenwirkungen und durch eine Abhängigkeit von teuren Therapien limitiert sein.

**Hypothese/Ziele** – Die gegenwärtige Studie zielte darauf ab, die möglichen günstigen Auswirkungen von fluoreszierender Lichtenergie (FLE) auf Fälle mit CPF zu erfassen.

**Tiere** – Vier Hunde mit perianalen Fisteln.

**Methoden und Materialien** – FLE wurde als einzige Erhaltungstherapie einmal wöchentlich in Form von zwei konsekutiven Anwendungen in derselben Sitzung für jeden Hund angewendet, bis die klinischen Zeichen signifikant verbessert waren, wobei sechs Wochen lang eine wöchentliche Untersuchung durchgeführt wurde. Die Hunde wurden anhand einer Messung der Größe der Veränderungen am Anfang der Studie und dann wöchentlich alle sechs Wochen mittels Planimetrie Software beurteilt. Die BesitzerInnen zeichneten eine Lautäußerung auf, bewerteten die Frequenz von Tenesmus während der Defäkation ihrer Haustiere und die Frequenz des perianalen Leckens auf einer Skala von 0-5, um die Verbesserung durch die Therapie zu erfassen.

**Ergebnisse** – Alle Hunde verbesserten sich mit FLE, wobei sowohl die Schmerzäußerungen, wie auch das Pressen und Lecken nach zwei Wochen ( $P = 0,002$ ) signifikant reduziert waren. Nach einer fünf wöchigen FLE Therapie waren die Hautveränderungen signifikant kleiner ( $P = 0,04$ ). Nur bei einem Hund waren mehr als sieben Anwendungen nötig. Es wurden keine Nebenwirkungen beschrieben.

**Schlussfolgerung und klinische Bedeutung** – Die FLE könnte eine vielversprechende alternative Therapie für CPF darstellen.

## 要約

**背景** – 犬の肛門周囲瘻（CPF）は、肛門周囲の皮膚に罹患する重度の痛みを伴う衰弱性皮膚疾患である。CPFはしばしば犬および飼い主の双方の生活の質を妨げる。従来の医学的治療は、免疫抑制療法の使用を伴う。ただし、病変の良好な解決は、飼い主のコンプライアンスの悪さ、薬物有害反応、および高額な治療への依存によって制限される可能性がある。

**仮説/目的** – 本研究は、CPF症例に対する蛍光光エネルギー（FLE）の潜在的な利点を評価することを目的とした。

**供試動物** – 活動的な肛門周囲瘻のある犬4頭。

**材料と方法** – FLEを、臨床症状が大幅に改善されるまで、6週間の週次評価で、各犬同じセッションで週に1回、2回の連続適用で、FLEを唯一の管理療法として適用した。犬は、試験開始時に病変サイズを測定し、その後、面積測定ソフトウェアを使用して6週間にわたって毎週評価された。飼い主は、ペットの排便時の発声およびしぶりの頻度スコアを記録し、肛門周囲の舐性行動の頻度を0–5ポイントスケールで記録し、治療に対する反応を評価した。

**結果** – FLEによりすべての犬が改善し、2週間後に発声、しぶり、舐性行動を大幅に軽減した（ $P = 0.002$ ）。FLE療法の5週間後、病変領域は有意に減少した（ $P = 0.04$ ）。1頭の犬だけが7回以上の適用を必要とした。有害事象は報告されていない。

**結論と臨床的重要性** – FLEはCPFの有望な代替療法になる可能性がある。

## 摘要

**背景** – 犬肛門瘻(CPF)是一种影响肛周皮肤的严重、疼痛、使机体衰弱的皮肤疾病。常干扰犬和主人的生活质量。常规药物治疗涉及使用免疫抑制剂;然而,宠主依从性差、药物不良反应和治疗昂贵可能造成病变的疗效有限。假设/目的-本研究旨在评估荧光灯光能(FLE)对CPF病例的潜在效果。

**动物** – 4只活动性肛周瘻患犬。

**方法和材料** – FLE作为唯一的管理治疗手段,每周一次,每只犬在同一时段连续应用两次,直至临床体征显著改善,每周评估一次,持续6周。在研究开始时,使用平面测量软件测量犬的病变大小,然后每周测量一次,持续6周。主人在0-5分量表上记录宠物排便期间的嘶叫和用力频率评分,以及肛周舔舐频率,以评估治疗效果。

**结果** – FLE让所有犬均有改善,两周后叫声、用力和舔舐显著减少( $P=0.002$ )。FLE治疗5周后,皮损面积显著减小( $P=0.04$ )。只有一只犬需要7次以上的治疗。未发现不良反应。

**结论和临床重要性** – FLE可能是CPF的一种有前景的替代疗法。

## Resumo

**Contexto** – A fístula perianal canina (FPC) é uma dermatopatia grave, dolorosa e debilitante que afeta a região perianal. Frequentemente, ela interfere na qualidade de vida de ambos o cão e o proprietário. O tratamento médico convencional envolve o uso de terapia imunossupressiva; entretanto, o sucesso na resolução das lesões pode ser limitado devido ao baixo comprometimento do proprietário, aos efeitos adversos dos medicamentos e ao alto custo das medicações.

**Hipótese/Objetivos** – O presente estudo teve como objetivo avaliar os potenciais benefícios da energia da luz fluorescente (ELF) nos casos de FPC.

**Animais** – Quatro cães com fístulas perianais ativas.

**Métodos e materiais** – A ELF foi aplicada em monoterapia uma vez por semana com duas aplicações consecutivas na mesma sessão para cada cão até que os sinais clínicos melhorassem significativamente, com avaliações semanais por um período de seis semanas. Os cães foram avaliados através da mensuração do tamanho das lesões no início do estudo e depois semanalmente durante seis semanas, utilizando um software de planimetria. Para avaliar a resposta à terapia, os proprietários registraram pontuações de frequência de vocalização e esforço durante a defecação de seu animal e da frequência de lambedura da região perianal em uma escala de 0 a 5 pontos.

**Resultados** – Todos os cães melhoraram com ELF, alcançando uma redução significativa na vocalização, esforço e lambedura após duas semanas ( $P = 0,002$ ). Após cinco semanas de terapia com ELF, as áreas lesionais diminuíram significativamente ( $P = 0,04$ ). Apenas um cão exigiu mais de sete aplicações. Nenhum evento adverso foi relatado.

**Conclusão e importância clínica** – A ELF pode ser uma terapia alternativa promissora para FPC.