

## Fluorescence biomodulation in the management of canine interdigital pyoderma cases: a prospective, single-blinded, randomized and controlled clinical study

Andrea Marchegiani\* , Andrea Spaterna\*, Matteo Cerquetella\*, Adolfo M Tambella\* ,  
Alessandro Fruganti\* and Susan Paterson† 

\*School of Biosciences and Veterinary Medicine, University of Camerino, via Circonvallazione 93/95, I-62024 Matelica, MC Italy

†Virtual Vet Derms Ltd., Lakeview, 3 High Birkrigg Park, Stainton, Kendal, Cumbria, LA8 0DY, UK

Correspondence: Andrea Marchegiani, School of Biosciences and Veterinary Medicine, University of Camerino, via Circonvallazione 93/95, I-62024 Matelica, MC, Italy. E-mail: andrea.marchegiani@unicam.it

**Background** – Interdigital pyoderma is a common multifactorial, inflammatory disease of the canine interdigital skin. Lesions commonly become infected secondarily. In addition to management of the underlying cause, management of the chronic inflammatory changes in the interdigital skin created by secondary infection and by the release of keratin into deep tissues is required. Fluorescence biomodulation appears to modulate the inflammatory process in dermatological disorders and has shown promise in preliminary studies evaluating its use in superficial and deep pyoderma in dogs.

**Hypothesis/Objectives** – To evaluate the effect of a fluorescence biomodulation (FB) system used in conjunction with systemic antibiotic on clinical manifestations of canine interdigital pyoderma (CIP), compared to dogs treated with antibiotic alone.

**Animals** – Thirty-six dogs diagnosed with CIP.

**Methods and materials** – Dogs were randomly allocated to treatment groups of either antibiotic alone (Group A) or antibiotic plus twice-weekly FB application (Group B). Dogs were scored over a 12 week period on the basis of two measured parameters: a global lesion score composed of four different lesions types and neutrophil engulfing bacterial scores.

**Results** – A statistically significant decrease was seen by Week 3 in both measured parameters for Group B compared to Group A. The mean time-to-resolution of lesions was 4.3 weeks in Group B and 10.4 weeks in Group A.

**Conclusion and clinical importance** – The FB system shows promise as an adjunct therapy to systemic antibiotic use in the management of CIP.

### Introduction

Canine interdigital pyoderma (CIP) is a chronic inflammatory skin problem affecting the pedal skin.<sup>1–4</sup> Often referred to as pedal folliculitis and furunculosis, pododermatitis or interdigital “cysts”, the condition is a complex, multifaceted disease. Affected tissues may include interdigital spaces, footpads and nail folds or combinations thereof.<sup>4</sup> Veterinarians commonly find it frustrating both to diagnose the underlying disease and institute appropriate therapy.<sup>4</sup> The clinical appearance of the lesions on the paw can be identical regardless of

the underlying condition; CIP has been associated with allergy (atopic dermatitis, cutaneous adverse food reaction), ectoparasites (*Demodex canis*), endocrine disease (hypothyroidism, hyperadrenocorticism), foreign bodies and conformational problems.<sup>5</sup> Secondary infection is a common sequela to the underlying disease. Localized areas of folliculitis can progress to furunculosis leading to a significant foreign body reaction due to the release of keratin into the skin with the formation of fistulae and draining tracts. This can be caused through trauma due to over-grooming in pruritic dogs or through conformational defects which can lead to abnormal weight-bearing on haired skin leading to comedone formation and folliculitis.<sup>3,4,6</sup>

Resolution of the infection often requires prolonged courses of antibiotics and relapse is not uncommon (even if the underlying trigger is managed) due to the persistence of foreign material within the skin. In addition to chronic antibiotic therapy, many clinicians use topical or systemic anti-inflammatory drugs including glucocorticoids and ciclosporin to manage the foreign body reaction created by the presence of follicular material released into the skin. In some severe cases, conventional or laser

Accepted 29 June 2019

**Conflict of Interest:** Klox Technologies Limited funds a full-time research position at the University of Camerino. Susan Paterson is a consultant for Klox and ICF; in the past two years, she has received honorarium or hospitality from Elanco, Dechra and Royal Canin. The other authors have not declared any conflicts of interest.

**Source of Funding:** Klox (only) provided the equipment and gel for the treatment of the cases.

surgical intervention has been used when the chronic fibrosing interdigital lesions become unamenable to medical therapy.<sup>6–8</sup>

Low-energy light, also known as photobiomodulation (PBM), has been shown to have beneficial effects in wound healing and other dermatological conditions.<sup>9,10</sup> Mixed results have been reported for use of PBM in dogs with dermatological pedal lesions. One pilot study of five dogs reported the beneficial effects of low-level laser therapy (a form of PBM) in sterile pyogranulomatous pododermatitis cases; a larger study failed to report an improvement in pedal pruritus and pedal lesions scores in atopic dogs.<sup>11,12</sup> The KLOX Fluorescence Biomodulation System (KFBS) consists of a blue light-emitting diode (LED) device and a topical photoconverter gel, which when illuminated by the LED device, emits low-energy light in the form of fluorescence.<sup>13</sup> *In vivo* and *in vitro* studies have shown that KBFS can modulate inflammatory mediators [such as tumor necrosis factor (TNF)- $\alpha$  and interleukin (IL)-6] and stimulate growth factors [such as transforming (TGF)- $\beta$ , fibroblast (FGF), platelet-derived (PDGF) and vascular endothelial (VEGF) growth factors]. These effects were observed only in response to the combination of gel and lamp illumination, rather than the LED lamp on its own or placebo gel illuminated with the LED lamp.<sup>14</sup> A veterinary KBFS system has been developed and preliminary canine studies of superficial bacterial folliculitis<sup>15</sup> and deep pyoderma<sup>16</sup> have shown encouraging results and an excellent safety profile with no therapy-related adverse effects.

The aim of the present study was to evaluate the effect of Phovia on clinical manifestations of CIP. The study was designed to assess whether the combination of Phovia with systemic antibiotics, selected on the basis of culture and susceptibility, could lead to a reduction in time to clinical healing, measured as the percentage of dogs that reached clinical resolution by six weeks, compared to dogs which received antibiotics alone. Response to therapy was assessed by reduction in lesion scores and improvement in lesion site cytological findings, as measured by a reduction in the numbers of neutrophils engulfing bacteria.

## Methods and materials

### Study design

This study was designed as a prospective, single-blinded, randomized study conducted in Italy between February 2017 and September 2018. A total of 36 dogs with interdigital lesions were randomly assigned to either Group A (systemic antibiotic, 17 dogs) or Group B (systemic antibiotic plus Phovia, 19 dogs) using iMEDNET cloud-based software (MedNet Solutions; Minnetonka, MN, USA) in a 1:1 ratio, based on a randomization list created using SAS software v9.4 (SAS; Cary, NC, USA). Table 1 lists the signalment and variables that could impact on the response to treatment per group (breed, coat, weight, body condition score). The principal investigator (PI) examined the dogs on the day of enrolment and remained blinded on group allocation and treatment received until the end of the study. The collaborating investigator, who was not blinded, performed randomization and treatment allocations as well as all other scheduled assessments and treatments, and uploaded lesion photographs to iMEDNET for scoring by the PI. The study protocol was approved by the University Ethics Committee, and dog owners signed an informed consent before inclusion.

### Study objects and inclusion/exclusion criteria

Enrolled dogs had signs of interdigital pyoderma (CIP) defined as an inflammatory disease affecting the interdigital skin presenting with a range of clinical lesions including crusted papules, haemorrhagic vesicles and bullae, haemorrhagic crust, ulcers, erosions and fistulae with draining tracts.<sup>17</sup>

Due to the lack of a validated scoring systems for CIP, the study investigators developed an empirical scoring chart based on a 0–4 score of four lesion types, described in Table 2, resulting in a global lesion score (GLS) range of 0–16. For inclusion in the study, dogs had to score 3 or 4 in at least one of these four lesion types. For dogs that presented with a range of different lesions in the same paw, the entire foot was scored. Only one paw per dog was scored and always the same paw. When more than one paw was affected at enrolment, the most severely affected paw was selected for the study (the one scoring highest).

All dogs underwent culture and sensitivity swab sampling at the time of enrolment. Samples were taken from fistulae with draining tracts, ulcers or erosions and under crusts, if present. If a bacterial isolate was resistant to the standard antibiotic treatment (cefalexin), an alternative antibiotic was chosen based on the susceptibility profile. If the bacterial isolate was resistant to all antibiotics tested, then the dog was excluded from the study. The exclusion of these dogs was primarily to avoid confounding results by ensuring that effective antibiotic therapy was implemented in all cases. Ethically, it also was deemed inappropriate to use an unproven form of therapy in these cases, so other surgical and topical therapies were instituted.

In the two weeks before and throughout the course of the study systemic antihistamines, antibiotics, glucocorticoids, ciclosporin, oclacitinib or additional topical treatments including anti-inflammatory or antimicrobial products were not permitted. Lokivetmab was unavailable as a treatment option. Feeding and housing conditions were maintained on a consistent basis during the length of the study. During the enrolment visit, skin scrapings and tape strips were evaluated in every dog for *Demodex* and *Malassezia* infestation; blood and urine samples were obtained for complete blood count, serum biochemistry, urinalysis and endocrine profile. Dogs with parasitic dermatoses, fungal/yeast infections, leishmaniasis, endocrine or metabolic disorders, allergic pruritus, cutaneous neoplasia or kidney malfunction were excluded from the study. Dogs younger than 12 months of age or showing any signs of systemic ill health or systemic comorbidities, pregnant or lactating bitches, or dogs with more generalized signs of skin disease were not enrolled in the study.

The use of concurrent flea control and shampoo without antimicrobial activity was permitted and recorded. After enrolment dogs could be excluded due to poor compliance with the study protocol instructions regarding visits and medication, or due to severe adverse effects to any of the products used, as well as the development of any further comorbidities during the study that could confound results.

**Table 1.** Description of signalment data for enrolled dogs in Group A (antibiotics) and Group B (antibiotics and Phovia)

	Group A	Group B
Breed (n)		
Mixed breed	10	11
German shepherd dog	3	2
Boxer	1	0
Bulldog	1	1
Dobermann	1	0
Italian Bracco	1	1
Labrador retriever	0	2
Pitbull	0	2
Coat		
Long (n)	7	9
Short (n)	10	10
Weight (kg) mean (SD)	34.82 (9.36)	33.79 (7.04)
Body condition score, mean (SD)	5.4 (0.7)	5.7 (0.7)

**Table 2.** Scoring system for each case (only one foot scored per case)

Lesion type		Haemorrhagic vesicles/bullae	Fistula with draining tracts	Haemorrhagic crust/papules	Ulcers/erosions
Score	Grade	Lesion assessment for each foot			
0	Healed	Absent	Absent	Absent	Absent
1	Mild	Healing lesion	Healing nondraining lesions only	1 small area	Superficial erosions only
2	Moderate	1–2 primary lesions	Single active draining lesion	2 small areas	Single small area of ulceration, no other lesions
3	Severe	3–4 primary lesions	1–2 active draining lesions with other lesions	3–4 more extensive areas	Single more extensive area combined with other lesions or two areas of extensive ulceration without other lesions
4	Very severe	≥5 primary lesions	≥3 active draining lesions with other lesions	≥5 extensive areas	≥2 extensive areas combined with other lesions or 3 or more extensive areas

Note: Small defined as ≤1 cm in diameter. Extensive lesions defined as >1 cm in diameter.

### Study intervention

At enrolment, all dogs were given systemic antibiotic therapy (cefalexin 20 mg/kg per os twice daily) and a swab sample was taken for culture and sensitivity analysis, with results provided within five days. If the identified bacteria were not susceptible to this antibiotic, another was chosen according to sensitivity report. For all dogs, antibiotic therapy was continued until seven days after clinical resolution was determined.

Dogs in Group B received Phovia (Phovia™, Klox Technologies Limited; Dublin, Ireland) applied twice weekly until clinical resolution was determined, in addition to the antibiotic therapy. The Phovia procedure consisted of applying a ≈2 mm layer of gel in the lesions and illuminating with the blue LED device that delivers noncoherent blue light with peak wavelength between 440 and 460 nm and a power density of between 55 and 129 mW/cm<sup>2</sup>, for 2 min, at approximately 5 cm distance. After illumination, the gel was gently removed using sterile gauzes immersed in sterile saline solution. In dogs presenting with lesions on more than one paw, although only one paw was used for the assessment, all affected paws received treatment as per group allocation.

### Clinical assessment

Assessments were performed on days 0, 7, 14, 21, 28, 35 and 42 for subjects that reached clinical resolution at Day 42 or before. For those dogs not reaching clinical resolution by Day 42 (Week 6), further assessments were conducted during visits on days 56, 70 and 84 until clinical resolution was determined. Dogs that did not reach clinical resolution by Week 12 continued treatment until clinical resolution was determined.

Clinical resolution was determined when the four lesion types scored as per Table 2 had been reduced to either 1 or 0 (mild or absent). Cytological assessment of stained impression smears was taken by pressing a clean microscope slide directly onto an open lesion. The neutrophil engulfing score (NES, 0–4) as described in Table 3 was counted by an external clinical pathologist who also was blinded to the identity of each case. Numbers of neutrophil engulfing

**Table 3.** Severity of neutrophil engulfing scores (NES)

NES score	Numbers of neutrophils engulfing bacteria*
0	None seen
1	<1
2	1–4
3	5–10
4	>10

\*Numbers of neutrophil engulfing bacteria per high powered field were counted at ×500 magnification and an average was taken over 10 microscopic fields.

bacteria per high powered field were counted at ×500 magnification and an average was taken over 10 microscopic fields.

Dogs that had clinical resolution by 12 weeks of treatment (Day 84 visit) were enrolled for a further four month follow-up period to assess for recurrence of lesions. Dogs that did not show resolution until after 12 weeks were not enrolled in the follow-up period in order that proposed study timelines could be met. Recurrence was defined as the re-appearance of one or a combination of lesions at the same site as affected previously. During the follow-up period, owners were asked to contact the hospital if they observed any signs of recurrence of lesions. In addition, all owners were contacted by telephone at one, two and three months post clinical resolution to check if any signs of relapse were noticed or whether the dog had required any antibiotic or anti-inflammatory therapy for CIP or any other condition. All owners were required to attend a final clinical examination, four months after the start of the follow-up period. All data analyses (Student's *t*-test, Fisher exact test, Wilcoxon–Mann–Whitney U-tests) were conducted using SAS v9.4; values of  $P \leq 0.05$  were considered significant.

### Results

In total, 36 dogs were enrolled of which 17 were randomized to Group A and 19 to Group B. During the study, four dogs were withdrawn; three from Group A were excluded at enrolment for the presence of multi-resistant *Staphylococcus* spp. and one dog from Group B was excluded at Week 8 for poor owner compliance leading to the nonavailability of the dog for reassessment. No significant differences in sex, age, body weight or breed of dog were identified between the two groups (Table 1). In no case did the dog's condition deteriorate after commencement of the trial and no adverse effects were recorded in either group.

*Staphylococcus* spp. was identified as the predominant bacterial isolate in all cases (*S. pseudintermedius*, *S. aureus*) and other bacteria were found in co-culture (Table S1). In the 32 dogs that completed the trial, all but three isolates were sensitive to cefalexin. For the cefalexin-resistant isolates, an appropriate oral antibiotic was selected based on culture and susceptibility (Group A, one dog received enrofloxacin 5 mg/kg once daily, one dog received amoxicillin-clavulanic acid 20 mg/kg twice daily; Group B, a single dog received enrofloxacin 5 mg/kg once daily). At enrolment, no significant difference was present between the global

lesion scores for the two groups (Group A average GLS  $8.32 \pm 2.45$  SD; Group B average GLS  $8.5 \pm 2.81$  SD) when *t*-tested.

### Time to clinical resolution

From Week 3 to study end, there was a statistically significant improvement in the time to clinical resolution in favour of Group B as shown in Figure 1. The percentage of dogs that achieved clinical resolution by Week 6 was 26.5% and 84.6% for groups A and B, respectively. This was a highly statistically significant difference in favour of Group B treated dogs ( $P < 0.001$ ). In Group A, the mean time to achieve clinical resolution was  $10.4 \pm 4.9$  weeks (median 10.0 weeks), whereas in Group B clinical resolution occurred by  $4.3 \pm 2.2$  weeks (median 3.5 weeks). Two exemplar cases from Group B that help illustrate rapid healing in the antibiotic plus Phovia group are shown in Figures S1 and S2, which show clinical resolution in two and four weeks, respectively.

### GLS and NES

From Week 3 to study conclusion, there was a statistically significant improvement in the mean GLS scores in favour of Group B as shown in Figure 2. There was a statistically significant improvement in mean NES scores in favour of Group B at weeks 3, 4 and 6, as shown in Figure 3.

### Follow-up period

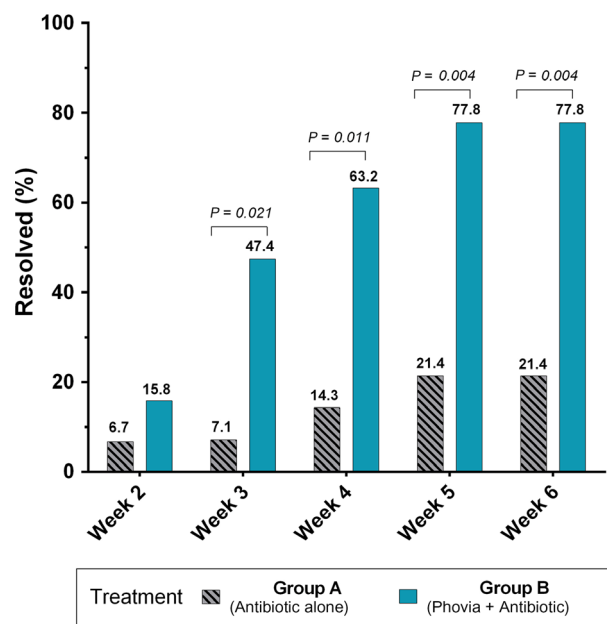
Six dogs from Group A and 16 from Group B were enrolled for the follow-up assessment period. There were fewer dogs in Group A as more dogs in this group did not achieve clinical resolution by week 12, which was one of the requirements to enrol in the follow-up period. Recurrence of interdigital pyoderma was recorded in two dogs, one in each group (17% recurrence rate in Group A, 6% in Group B). The dog from Group A had a GLS of 4 at its reassessment whereas the dog in Group B scored 5.

### Discussion

Similarly to previous studies in dogs with superficial and deep pyoderma,<sup>15,16</sup> in this study of dogs with CIP, the Klox FB System Phovia was able to reduce the time to clinical resolution and accordingly the length of the course of antibiotic therapy required when used as an adjunct therapy with systemic antibiotics versus systemic antibiotics alone.

To the best of the authors' knowledge, there is no recognized scoring system for CIP. Therefore, for this study a scoring system was designed to include the most commonly described lesions including haemorrhagic vesicles, papular eruptions, haemorrhagic crusts, erosions, ulcers and fistulae with draining tracts.<sup>1-4</sup>

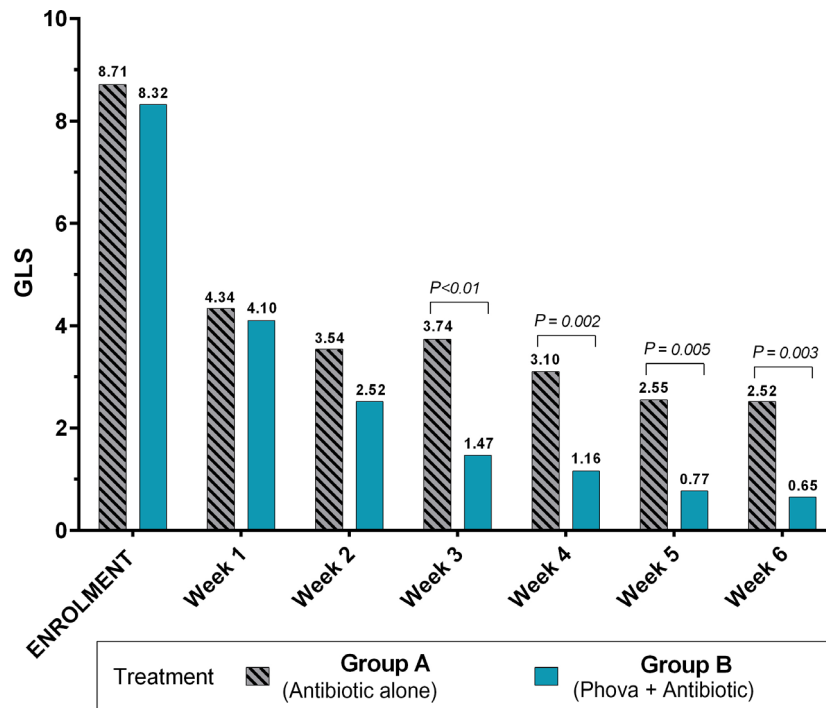
Although comedones also are described in cases of CIP, these were not used to assess the progression of lesions because it was felt they were unlikely to resolve during the time period of the trial. Given no significant differences in global lesion scores were present between the two groups at the time of enrolment, it was assumed that changes in scores between the two groups with the progression of the study would be an indication of the differing responses



**Figure 1.** Percentage of dogs healed by treatment and study week. \**P*-value based on two-sided Fisher's Exact test.

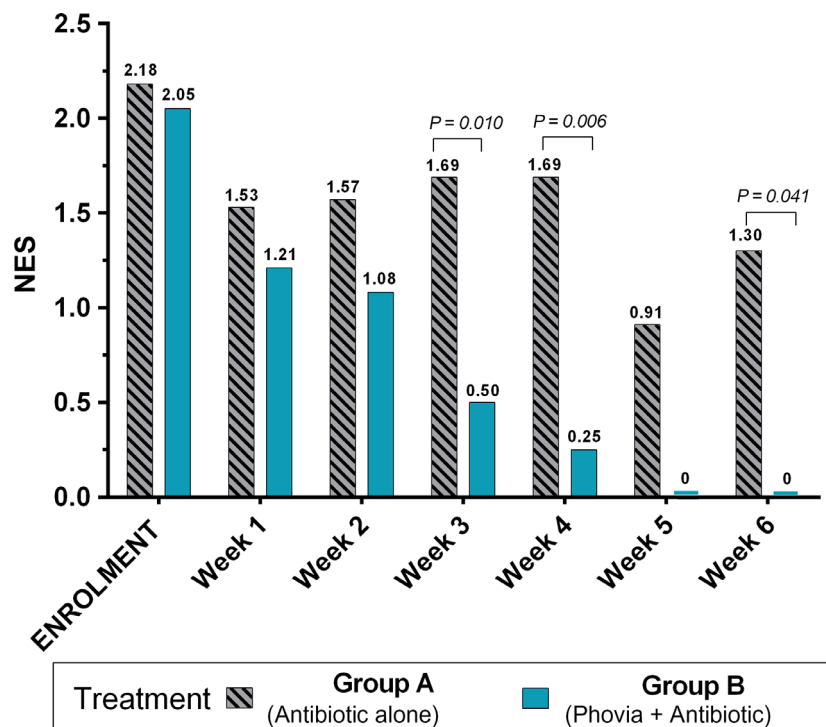
to therapy. Pruritus was not reported as a consistent finding by owners so this was not included as a means of recording response to therapy; however, retrospectively this would have been a useful inclusion criterion.

The diagnosis of pyoderma was based on the characteristic skin lesions and the cytological evidence of intracellular bacteria.<sup>18</sup> Culture and susceptibility were undertaken to identify the bacteria and allow more specific prescription of antibiotics.<sup>19,20</sup> Neutrophils were chosen as the inflammatory cell to monitor as these predominate in most cases of pyoderma. Phagocytosed bacteria within the cytoplasm of neutrophils are recognised as a better indicator of the presence of infection rather than absolute bacterial numbers, as extracellular bacteria can be contaminants. The degree of neutrophil engulfment was therefore deemed to be the quickest and most accurate way to assess clinical resolution of infection.<sup>20,21</sup> This was recorded as NES. There was a significantly quicker reduction in NES in the Phovia plus antibiotic group compared to the antibiotic alone group. This suggests the infective process resolves quicker when Phovia was combined with antibiotics. The reason for this is unclear, as the specific mode of action of KFBS has not yet been fully elucidated. Although the use of KFBS has been described in veterinary studies in the management of both deep and superficial pyoderma, a specific anti-staphylococcal effect has not been demonstrated.<sup>14,15</sup> An *in vitro* study to assess the bactericidal activity of blue light phototherapy on both methicillin-susceptible *Staphylococcus pseudintermedius* (MSSP) and methicillin-resistant *S. pseudintermedius* (MRSP) showed no significant reduction of colony counts for either bacteria.<sup>22</sup> However, it should be noted that the KFBS system uses both a blue light and fluorescent light emitted from the photoconverter gel, making a comparison of the two studies difficult. The ability of KFBS to accelerate healing in both infectious and noninfectious inflammatory human skin conditions has been described, as well as its ability



**Figure 2.** Global lesions scores (GLS) by treatment and study week.

\*P-value based on two-sided Wilcoxon–Mann–Whitney U-test. From Week 3, a statistically significant decrease of GLS was seen in favour of Group B (antibiotic + Phovia).



**Figure 3.** Neutrophil engulfing bacteria (NES) by treatment and study week.

\*P-value based on two-sided Wilcoxon–Mann–Whitney U-test. From Week 3, a statistically significant decrease of NES was seen in favour of Group B (antibiotic + Phovia).

to downregulate inflammatory mediators.<sup>23</sup> It may therefore be these properties that are responsible for the quicker resolution of the lesions in these cases of CIP. *In vitro* studies evaluating how FB modulates cellular activity to produce improvement in human inflammatory skin

conditions demonstrated a range of mechanisms, including that the production of inflammatory cytokines, TNF alpha and IL-6, produced by both human dermal fibroblasts (HDF) and human epidermal keratinocytes in response to chronic inflammation was reduced on

exposure to KFBS. Moreover, FB was shown to significantly increase collagen production from HDFs compared to control fibroblasts.<sup>24,25</sup>

Canine interdigital pyoderma is a painful and debilitating disease for dogs. Some studies have reported that the quality of life (QoL) of dogs and their owners is profoundly affected by skin disease,<sup>26,27</sup> and the measurement of the QoL of affected dogs and their owners has the potential to provide a useful tool for assessing disease severity and treatment efficacy. A further improvement in this study could have been recording the QoL scoring for both the pet and the owner throughout the trial period.

In conclusion, the present study suggests that KFBS, when used as an adjunct therapy with systemic antibiotics, can accelerate clinical resolution in the management of CIP.

## References

- Bloom P. Idiopathic pododermatitis in the dog: an uncommon but frustrating disease. *Vet J* 2008; 176: 123–124.
- Breathnach RM, Fanning S, Mulcahy G *et al.* Canine pododermatitis and idiopathic disease. *Vet J* 2008; 176: 146–157.
- Duclos D. Canine pododermatitis. *Vet Clin North Am Small Anim Pract* 2013; 43: 57–87.
- Bajwa J. Canine pododermatitis. *Can Vet J* 2016; 57: 991–993.
- Miller WH, Griffin CE, Campbell KL. *Muller and Kirk's Small Animal Dermatology*, 7<sup>th</sup> edition. St Louis, MO: Elsevier Mosby; 2013: 106–107.
- Duclos DD, Hargis AM, Hanley PW. Pathogenesis of canine interdigital palmar and plantar comedones and follicular cysts, and their response to laser surgery. *Vet Dermatol* 2008; 19: 134–141.
- Swaim SF, Lee AH, MacDonald JM *et al.* Fusion podoplasty for the treatment of chronic fibrosing interdigital pyoderma in the dog. *J Am Anim Hosp Assoc* 1991; 27: 264–274.
- Papazoglou LG, Ellison GW, Farese JP *et al.* Fusion podoplasty for the management of chronic pedal conditions in seven dogs and one cat. *J Am Anim Hosp Assoc* 2011; 47: e199–e205.
- Hochman L. Photobiomodulation therapy in veterinary medicine: a review. *Top Companion Anim Med* 2018; 33: 83–88.
- Opel DR, Hagstrom E, Pace AK *et al.* Light-emitting diodes: a brief review and clinical experience. *J Clin Aesthet Dermatol* 2015; 8: 36–44.
- Perego R, Proverbio D, Zuccaro A *et al.* Low-level laser therapy: case-control study in dogs with sterile pyogranulomatous pododermatitis. *Vet World* 2016; 9: 882–887.
- Stich AN, Rosenkrantz WS, Griffin CE. Clinical efficacy of low-level laser therapy on localized canine atopic dermatitis severity score and localized pruritic visual analog score in pedal pruritus due to canine atopic dermatitis. *Vet Dermatol* 2014; 25: 464–e74.
- Romanelli M, Piaggese A, Scapagnini G *et al.* Evaluation of fluorescence biomodulation in the real-life management of chronic wounds: the EUREKA trial. *J Wound Care* 2018; 27: 744–753.
- Scapagnini G, Marchegiani A, Rossi G *et al.* Management of all three phases of wound healing through the induction of fluorescence biomodulation using fluorescence light energy. In: *Photonic Diagnosis and Treatment of Infections and Inflammatory Diseases II: Proceedings of SPIE BiOS*, San Francisco, CA, USA; 2019; vol. 108630. Available at <https://www.kloxtechnologies.com/wp-content/uploads/2019/03/SPIE.pdf>. Accessed March 7, 2019.
- Marchegiani A. Klox Fluorescence Biomodulation System (KFBS), an alternative approach for the treatment of superficial pyoderma in dogs: preliminary results. In: *Proceedings of 61st BSAVA Congress*; Birmingham, England; 2018; 442. (see <https://www.bsavalibrary.com/content/chapter/10.22233/9781910443590.ch67sec1>. Accessed 03/07/2019)
- Marchegiani A, Cerquetella M, Tambella AM *et al.* The Klox Biophotonic System, an innovative and integrated approach for the treatment of deep pyoderma in dogs: a preliminary report. *Vet Dermatol* 2017; 28: 545. (abstract).
- Miller WH, Griffin CE, Campbell KL. *Muller and Kirk's Small Animal Dermatology*. 7<sup>th</sup> edition. St Louis, MO: Elsevier Mosby; 2013: 201–203.
- Mendelson C, Rosenkrantz W, Griffin CE. Practical cytology for inflammatory skin disease. *Clin Tech Small Anim Pract* 2006; 21: 117–127.
- Shearer DH, Day MJ. An investigation of phagocytosis and intracellular killing of *Staphylococcus intermedius* by canine neutrophils in vitro. *Vet Immunol Immunopathol* 1997; 58: 219–230.
- Summers JF, Brodbelt DC, Forsythe PJ *et al.* The effectiveness of systemic antimicrobial treatment in canine superficial and deep pyoderma: a systematic review. *Vet Dermatol* 2012; 23: 305–329.
- Chammas PP, Hagiwara MK. Evaluation of neutrophilic function (chemotaxis, phagocytosis and microbicidal activity) in healthy dogs and in dogs suffering from recurrent deep pyoderma. *Vet Immunol Immunopathol* 1998; 64: 123–131.
- Schnedeker AH, Cole LK, Lorch G *et al.* In vitro bactericidal activity of blue light (465 nm) phototherapy on methicillin-susceptible and methicillin-resistant *Staphylococcus pseudintermedius*. *Vet Dermatol* 2017; 28: 463–e106.
- Shnitkind E, Yaping E, Geen S *et al.* Anti-inflammatory properties of narrow-band blue light. *J Drugs Dermatol* 2006; 5: 605–610.
- de FL, Hamblin MR. Proposed mechanisms of photobiomodulation or low-level light therapy. *IEEE J Sel Top Quantum Electron* 2016; 22: 7000417.
- Edge D, Mellegaard M, Dam-Hansen C *et al.* Fluorescent light energy: the future for treating inflammatory skin conditions? *J Clin Aesthet Dermatol* 2019; 12: E61–E68.
- Noli C, Colombo S, Cornegliani L *et al.* Quality of life of dogs with skin disease and of their owners. Part 2: administration of a questionnaire in various skin diseases and correlation to efficacy of therapy. *Vet Dermatol* 2011; 22: 344–351.
- Noli C, Minafo G, Galzerano M. Quality of life of dogs with skin diseases and their owners. Part 1: development and validation of a questionnaire. *Vet Dermatol* 2011; 22: 335–343.

## Supporting Information

Additional Supporting Information may be found in the online version of this article.

**Figure S1.** Case 1 clinical evaluation visit pictures.

**Figure S2.** Case 2 clinical evaluation visit pictures.

**Table S1.** Bacteria isolated from canine interdigital lesions.

## Résumé

**Contexte** – La pyodermite interdigitée est une maladie inflammatoire multifactorielle fréquente de la peau interdigitée du chien. Les lésions s'infectent fréquemment secondairement. En plus de la gestion de la cause sous jacente, le contrôle des modifications inflammatoires chroniques de la peau interdigitée créées par l'infection secondaire et par la libération de kératine dans les tissus profonds est nécessaire. La biomodulation par fluorescence semble moduler le processus inflammatoire des dermatoses et a montré des résultats prometteurs dans les études préliminaires évaluant son intérêt dans les pyodermites superficielles et profondes du chien.

**Hypothèses/Objectifs** – Evaluer les effets d'un système de biomodulation par fluorescence (FB) associé à une antibiothérapie systémique sur les manifestations cliniques des pyodermites interdigitées canines (CIP), comparé à une antibiothérapie seule.

**Sujets** – Trente-six chiens diagnostiqués avec CIP.

**Matériels et méthodes** – Les chiens ont été répartis au hasard dans les groupes traitement antibiotique seul (Groupe A) ou antibiotique plus application de FB deux fois par semaine (Groupe B). Les chiens ont été évalués pendant 12 semaines pour deux paramètres : un score lésionnel global composé de quatre types de lésions différentes et un score de phagocytose de bactéries par les neutrophiles.

**Résultats** – Une diminution statistiquement significative a été observée à la semaine 3 pour les deux paramètres mesurés pour le Groupe B comparé au Groupe A. Le temps de résolution moyen des lésions étaient de 4,3 semaines pour le Groupe B et 10,4 semaines pour le Groupe A.

**Conclusion et importance clinique** – Le système FB est prometteur en association à une antibiothérapie systémique pour la gestion des CIP.

## Resumen

**Introducción** – la pioderma interdigital es una enfermedad inflamatoria multifactorial común en la piel interdigital canina. Las lesiones comúnmente se infectan de forma secundaria. Además del manejo de la causa primaria, se requiere el manejo de los cambios inflamatorios crónicos en la piel interdigital creados por una infección secundaria y por la liberación de queratina en los tejidos profundos. La biomodulación por fluorescencia parece controlar el proceso inflamatorio en trastornos dermatológicos y se ha mostrado prometedora en estudios preliminares que evalúan su uso en pioderma superficial y profundo en perros.

**Hipótesis/Objetivos** – evaluar el efecto de un sistema de biomodulación de fluorescencia (FB) utilizado junto con un antibiótico sistémico en las manifestaciones clínicas de la pioderma interdigital canina (CIP), en comparación con los perros tratados con antibióticos solos.

**Animales** – treinta y seis perros diagnosticados con CIP.

**Métodos y materiales** – los perros se asignaron al azar a los grupos de tratamiento de antibióticos solos (grupo A) o antibióticos más la aplicación de FB dos veces por semana (grupo B). Los perros se calificaron durante un período de 12 semanas sobre la base de dos parámetros medidos: una valoración de lesión global compuesta por cuatro tipos de lesiones diferentes y valoraciones de bacterias fagocitadas por neutrófilos.

**Resultados** – a la semana 3 se observó una disminución estadísticamente significativa en ambos parámetros medidos para el grupo B en comparación con el grupo A. El tiempo medio de resolución de las lesiones fue de 4,3 semanas en el grupo B y de 10,4 semanas en el grupo A.

**Conclusión e importancia clínica** – el sistema FB se muestra prometedor como una terapia complementaria al uso sistémico de antibióticos en el tratamiento de la CIP.

## Zusammenfassung

**Hintergrund** – Die interdigitale Pyodermie ist eine häufige multifactorielle entzündliche Erkrankung der interdigitalen Haut des Hundes. Die Läsionen werden in der Regel sekundär infiziert. Zusätzlich zum Management der zugrunde liegenden Erkrankung ist es nötig, die chronisch entzündlichen Veränderungen in der interdigitalen Haut, die durch Sekundärinfektion und durch Freisetzung von Keratin in tiefere Gewebe entstehen, zu behandeln. Die Fluoreszenz Biomodulation scheint den entzündlichen Prozess bei dermatologischen Erkrankungen zu modulieren und hat in Vorstudien bereits vielversprechende Ergebnisse gezeigt, was ihren Einsatz bei superfizieller und tiefer Pyodermie des Hundes betrifft.

**Hypothese/Ziele** – Eine Evaluierung der Wirksamkeit des Fluoreszenz Biomodulationssystems (FB) in Verbindung mit systemischen Antibiotika auf die klinische Manifestation der interdigitalen Pyodermie des Hundes (CIP) im Vergleich zu Hunden, die nur mit Antibiotika behandelt wurden.

**Tiere** – Dreiunddreißig Hunde mit diagnostizierter CIP.

**Methoden und Materialien** – Die Hunde wurden zufällig in Behandlungsgruppen eingeteilt: entweder Behandlung nur mit Antibiotikum (Gruppe A) oder Antibiotikum plus zweimal wöchentlich FB Anwendung (Gruppe B). Die Hunde wurden über einen Zeitraum von 12 Wochen anhand von zwei Parametern beurteilt: ein globaler Beurteilungswert, der sich aus vier unterschiedlichen Läsionstypen zusammensetzte und bakterielle Werte anhand einer Ansammlung von Neutrophilen.

**Ergebnisse** – Eine statistisch signifikante Verminderung wurde ab Woche 3 für beide Messparameter in

Gruppe B im Vergleich zu Gruppe A gesehen. Die durchschnittliche Zeit bis zur Abheilung der Läsionen betrug in Gruppe B 4,3 Wochen und in Gruppe A 10,4 Wochen.

**Schlussfolgerung und klinische Bedeutung** – Das FB System zeigt sich als vielversprechende Zusatztherapie zu systemischer Antibiotikatherapie beim Management der CIP.

#### 要約

**背景** – 指趾間部膿皮症は、犬の指趾間部皮膚の一般的な多因子性炎症性疾患の一つである。病変は一般に二次感染する。根本要因の管理に加えて、二次感染および深部組織へのケラチンの放出によって引き起こされる指間皮膚の慢性炎症性変化の管理が必要とされる。蛍光バイオモジュレーションは皮膚科疾患における炎症過程を調節するようであり、犬の表在性および深在性膿皮症における蛍光バイオモジュレーションの使用を評価する予備研究において有望であることが示されている。

**仮説/目的** – 本研究の目的は、抗生物質単独で治療した犬と比較して、全身性抗生物質と併用して使用される蛍光バイオモジュレーション(FB)システムが犬指趾間部膿皮症(CIP)の臨床症状に及ぼす影響を評価することである。

**被験動物** – CIPと診断された犬36頭。

**材料および方法** – 被験犬を、抗生物質のみ(グループA)または抗生物質と週2回のFB投与(グループB)のいずれかの治療群に無作為に割り当てた。被験犬を、4つの異なる病巣タイプからなる全体的な病変スコアおよび好中球による食食細菌スコアによる2つの測定パラメータに基づいて12週間にわたって記録した。

**結果** – A群と比較してB群において、3週目までに両測定パラメータで統計的に有意な減少を認めた。病変の平均消失時間は、グループBでは4.3週、グループAでは10.4週であった。

**結論と臨床的重要性** – FBシステムは、CIP管理における全身性抗生物質の使用に対する補助療法として期待される。

#### 摘要

**背景** – 趾間膿皮病は犬趾間皮膚常见的多因素炎症性疾病,病变通常会继发感染。除了对潜在病因的管理之外,还需要对深层组织中的继发感染和角质释放形成的趾间皮肤慢性炎症进行管理。荧光生物调节似乎能够调节皮肤病中的炎症过程,并且在初步研究中显示,其有望应用于评估犬浅表和深层脓皮病。

**假设/目的** – 与仅用抗生素治疗的犬相比,评估全身抗生素治疗联合荧光生物调节(FB)系统对犬趾间脓皮病(CIP)临床症状的影响。

**动物** – 三十六只经诊断的CIP患犬。

**方法和材料** – 将犬随机分配到单独使用抗生素(A组)或抗生素加每周两次FB应用(B组)的治疗组。根据两个测量参数对犬进行12周的评分:由四种不同病变类型组成的全球病变评分和中性粒细胞吞噬细菌评分。

**结果** – 与A组相比,B组的两个测量参数在第3周观察到统计学意义上的显著下降。B组病变的平均消退时间为4.3周,A组为10.4周。

**结论和临床意义** – FB系统有望作为CIP管理中全身性抗生素治疗的辅助方法。

#### Resumo

**Contexto** – A pododermite interdigital é uma doença inflamatória comum, multifatorial que afeta a pele interdigital. As lesões frequentemente se tornam infectadas secundariamente. Além do tratamento da causa primária, é necessário o manejo das alterações inflamatórias crônicas da pele interdigital geradas pela infecção secundária e pela liberação de queratina nos tecidos profundos. A biomodulação fluorescente aparentemente é capaz de modular o processo inflamatório nas dermatopatias e tem demonstrado resultados promissores em estudos preliminares avaliando a sua utilização em pododermite superficial e profunda em cães.

**Hipótese/Objetivos** – Avaliar o efeito de um sistema de biomodulação fluorescente (BF) utilizado em associação com um antibiótico sistêmico nas manifestações clínicas da pododermite interdigital canina (PIC) comparado a cães tratados somente com antibiótico.

**Animais** – Trinta e seis cães diagnosticados com PIC.

**Métodos e materiais** – Os cães foram alocados aleatoriamente nos dois grupos de tratamento, sendo o Grupo A somente com antibiótico e o Grupo B antibiótico com aplicação de BF duas vezes por semana. Os cães foram avaliados durante um período de 12 semanas baseado em dois parâmetros: um escore global de lesão composto de quatro tipos diferentes de lesões e escores de fagocitose de bactérias por neutrófilos.

**Resultados** – Observou-se uma redução estatisticamente significativa nos dois parâmetros avaliados na Semana 3 para o Grupo B comparado ao Grupo A. O tempo médio de resolução das lesões foi 4,3 semanas para o Grupo B e 10,4 semanas para o Grupo A.

**Conclusões e importância clínica** – O sistema BF apresentou resultados promissores como terapia adjuvante à antibioticoterapia sistêmica no manejo da PIC.